

JOURNAL OF CLINICAL AND DIAGNOSTIC RESEARCH

How to cite this article :

GOPAL M, VARGHESE C. DRY EYE SYNDROME: A REVIEW . Journal of Clinical and Diagnostic Research [serial online] 2007 February [cited: 2007 Feb 3]; 1:22-31. Available from

http://www.jcdr.org.in/back_issues.asp?issn=0973-709x&year=2007&month=February&volume=1&issue=1&page=22-31&id=49

REVIEW ARTICLE

Dry Eye Syndrome: A Review

GOPAL M*, VARGHESE C

ABSTRACT

Dry eye syndrome is a recent discovery in the group of distinct treatable ocular diseases. This condition has been observed to be increasing wildly in the recent past due to civilizational changes. Dry eye is also referred to as tear film instability, a condition that typically develops from deficiencies of one or more components of the biologically complex pre-ocular tear film. Tears are composed of three layers: the outer oily lipid layer, the middle watery lacrimal layer, and the inner mucous or mucin layer. Each layer is produced by a different part of the eye, for example, the lacrimal gland produces the lacrimal layer. Therefore, a problem originating in any part of the eye can result in dry eyes. Clinically, dry eye cases represent a mixed picture of an allergy, an infection, and either drug or chemical toxicity. Therefore, dry eyes are often considered to be an accompaniment of Spring Catarrh, Follicular/Trachomatous conjunctivitis, Glaucoma, Aphakia, and so on, in clinical practice. Dry eye conditions are classified into those with adequate aqueous tear production, and those with aqueous tear deficiency. Lacrimal gland tear production can be determined clinically by means of a Schirmer test without anaesthesia (Schirmer 1) or by other more sophisticated tests for the evaluation of aqueous tear production and turnover. Certain specific pathological tests can differentially diagnose cases with aqueous tear production and aqueous tear deficiency. The market availability of artificial tear solutions or ocular surface wetting/lubricating eye drops, have played a significant role in the management of dry eye.

Key words: Dry eye syndrome, tear film, Sjogren's syndrome, Aqueous tear production, Aqueous tear deficiency, Schirmer test, Meibomian gland.

Introduction

An ocular surface disease results from a multi-factorial, heterogeneous disorder of the pre-ocular tear film. This disorder of the tear film is also termed dry eye. There are numerous disturbing factors that disrupt the equilibrium of the complex and stable system formed by the tear film and the ocular surface [1]. Dry eye, either alone or in combination with other conditions, is a frequent

cause of eye irritation that leads patients to seek ophthalmologic care [2]. The disease is usually not curable and may cause frustration to both patients and physicians although its symptoms often improve with treatment. Visual morbidity may cause dry eye and may compromise the results of corneal surgery.

The dry eye syndrome varies in severity, duration, and aetiology [3]. It has several causes. It occurs especially during menopause as a part of the natural aging process and as a side effect of systemic medications such as antihistamines, antidepressants, medications for blood pressure and

GOPAL EYE CLINIC, Barnala, Punjab, India
 Corresponding Author: DR. MOHNISH GOPAL.
 e-mail: harshita_bnl@yahoo.com

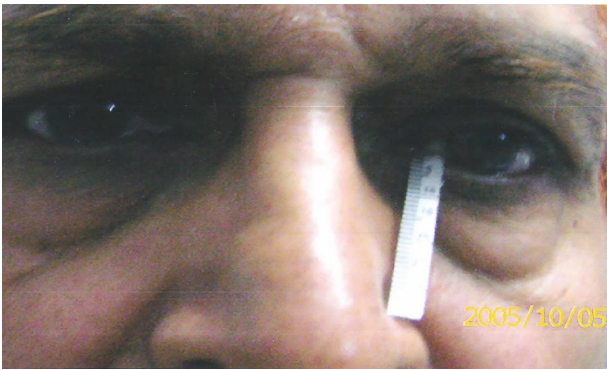

Fig 1: The nasal angular itching with dermatitis ,due to toxic hyperosmotic tear fluid , is common in mild dryness of eye , frequently seen in hair dye users. (photographed after permission from the patient, by Dr. Mohnish Gopal)

Parkinson's disease , and birth control pills. These medications decrease tear production and may lead to an increase in the severity of the symptoms

A dry, dusty, or windy climate, home or office air conditioning, or a dry heating system can also cause increased tear evaporation, resulting in dry eyes. Insufficient blinking during prolonged computer use can also lead to dry eyes. Long-term use of contact lenses is another cause. In reality, dry eyes are the most common complaint among contact lens wearers. The rubbing of the lenses against the conjunctiva seems to be a cause of dry eyes, making them wearers uncomfortable. Incomplete



Fig 2 Spring Catarrh cases on prolonged use of steroid drops develop typical dry eye signs giving rise to a paradoxical picture of inflammation without watering . (photographed after permission from the patient, by Dr. Mohnish Gopal)

closure of the eyelids, eyelid diseases, and a deficiency of the tear-producing glands are other causes. Recent research suggests that smoking can also increase the risk of dry eye syndrome.

Eyelid surgery or blepharoplasty has recently gained popularity for enhancing the appearances of individuals. Dry eye complaints are now occasionally associated with incomplete closure of eyelids following such a procedure. The elimination of these factors often lead to marked improvement in symptoms and may cure the problem to a certain extent. Dry eyes are also a symptom of systemic diseases such as Lupus, Rheumatoid arthritis, Rosacea, and Sjogren's syndrome (a triad of dry eyes, dry mouth, and either rheumatoid arthritis or lupus). The dry eye syndrome is more common in women, possibly due to hormone fluctuations. In some patients, the dry eye is caused either by a nonreversible deficiency of tear production or by a chronic condition leading to increased evaporation, such as blepharitis. In such cases the disease may exhibit a chronic nature, with waxing and waning severity of symptoms or a gradual increase in the severity of symptoms with time. Many patients who have moderate to severe dry eye have been observed to develop reversible conjunctival squamous metaplasia and punctate epithelial erosions of the conjunctiva and cornea. Complications such as ocular surface keratinization; corneal ulceration, scarring, thinning, or neo-vascularization, microbial keratitis, and sterile corneal keratolysis with possible perforation and severe visual loss are rarely observed in patients with severe dry eye.

Diagnostic classification

Dry eye conditions are classified, based on the ability of the lacrimal gland to produce tears, into those with adequate tear production, and those with tear deficiency. Meibomian gland dysfunction that results in lipid tear deficiency is observed in a majority of patients with adequate tear fluid in dry eye. Aqueous tear deficiency can be subclassified into non-Sjogren's syndrome and Sjogren's syndrome (SS) groups. Patients with non-Sjogren's tear deficiency have less severe symptoms and ocular surface disease than those with SS [4].

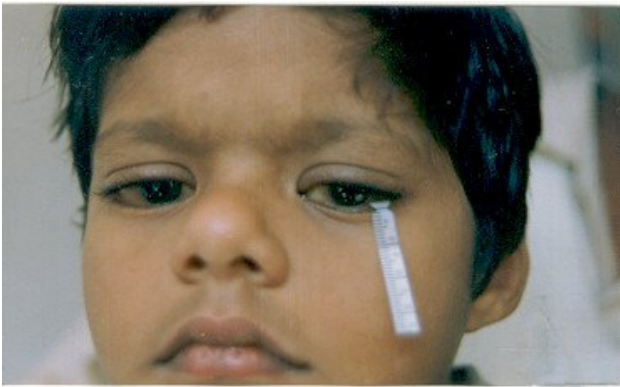

Fig 3 This child has severe bulbar & palpebral springcatarrh yet his Schirmer test is only 7mm. (photographed after parental consent, by Dr. Mohnish Gopal)



Fig 5 This patient has Trachoma grade iv with corneal opacities & operated Trichiasis and his Shirmer test is 3mm.

Trachoma has been notorious for parched / xerotic conjunctiva, Bitot spots and superficial corneal epitheliopathy amidst lot of reflex watering due to scarring of fornices and palpebral conjunctiva . This is like the proverbial thirsty fish amidst plenty of water. (photographed after permission from the patient, by Dr. Mohnish Gopal)

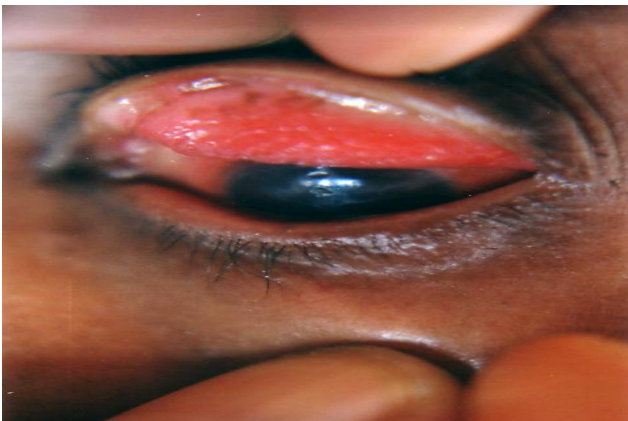

Fig 4 This case has large follicles with keratinisation of marginal palpebral conjunctiva (photographed after permission from the patient, by Dr. Mohnish Gopal)

Sjogren's syndrome is described as an autoimmune disorder characterized by infiltration and inflammation of the exocrine glands including the lacrimal and salivary glands, of the body. There are two forms of Sjogren's disease primary and secondary. **Primary Sjogren's** occurs alone, while **secondary Sjogren's** is found in association with other autoimmune disorders, such as Rheumatoid arthritis and Systemic lupus erythematosus. Regardless of the form of the disease, Sjogren's leads to severe aqueous deficiency due to an inflammatory infiltration and an eventual destruction of the lacrimal glands. The common complaints of patients with Sjogren's syndrome are dry eye symptoms and dry mouth.

For ocular management and for the overall health of the patient, proper identification of patients with symptoms of Sjogren's is extremely important. This is due to the possibility of concomitant autoimmune disease and a higher risk of the development of non-Hodgkin's lymphoma.

Non-Sjogren's syndrome is usually found in association with autoimmune diseases, such as Rheumatoid arthritis, Systemic lupus erythematosus, Wegeners granulomatosis, and Scleroderma. These autoimmune diseases cause tear fluid deficiency in a manner similar to that of Sjogren's syndrome. An inflammatory cascade is initiated at the level of the lacrimal gland and at the ocular surface by the circulating antibodies related to the specific autoimmune disease. The process is characterized by an infiltration of the lacrimal gland with T-lymphocytes and the release of cytokines and other inflammatory mediators that contribute to ocular surface inflammation and tissue destruction. Progressive lacrimal gland destruction and decreased tear fluid production is caused by the persistent infiltration of the inflammatory cells into the lacrimal gland.

Non-Sjogren's syndrome tear fluid deficiency can also be secondary to the use of medications.

There are numerous medications that contribute to dry eye, but the most common agents include anticholinergics, antidepressants, antihistamines,

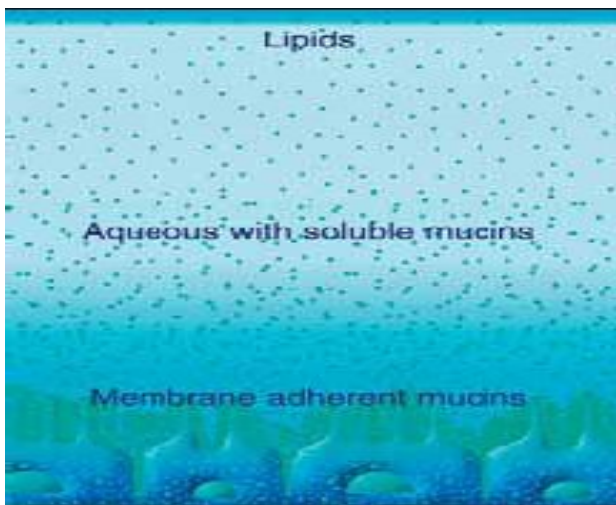


Fig 6 Schematic of tear film composition

antihypertensives, benzodiazepines, beta-blockers, and thiazide diuretics. Proper management of dry eye patients involves identifying these often-overlooked causes of tear fluid deficiency.

Evaporative dry eye is caused by lipid layer deficiency. Dry eye is caused by lipid layer deficiency that leads to increased evaporation of the underlying tear fluid layer. Lipid layer deficiency is typically caused by meibomian gland disease and dysfunction. Meibomian gland dysfunction is associated with conditions, such as blepharitis, acne rosacea, atopic keratoconjunctivitis, and seborrheic dermatitis [5]. The diagnosis of meibomian gland dysfunction is currently based on clinical examination of the meibomian gland openings. Transillumination biomicroscopy of the lower lid frequently reveals the dropout of the meibomian gland acini [6],[7].

Mucin layer deficiency is caused by goblet cell deficiency and is present in most cases of dry eyes. Without an adequate mucin layer, proper surface wetting and tear spread is impossible. Several particular disorders, such as chemical burns, Stevens Johnson syndrome and trachoma primarily affect goblet cells. In addition, goblet cell destruction can be caused by the use of topical medications and preservatives. Recent research has indicated that many circulating hormones, especially androgens and sex hormones, highly

influence tear secretion. These hormones seem to play a role in aqueous production and in the functioning of the meibomian gland. Androgens have been found to modulate the anatomy, physiology, and immune system of the lacrimal glands and to regulate the secretions of the meibomian glands. Therefore, the tear film is likely to be affected by alterations in hormonal balance. Although a relationship between circulating hormones and dry eyes has been confirmed, the exact relationship remains poorly understood. In contrast to popular belief that decreased tear production in menopausal women was caused by oestrogen deficiency, recent studies have shown that postmenopausal women receiving oestrogen replacement had a higher prevalence of dry eye than those not receiving hormone replacement. In addition, studies have also indicated that oestrogens appear to cause a reduction of metabolic activity and tear secretion by the lacrimal gland.

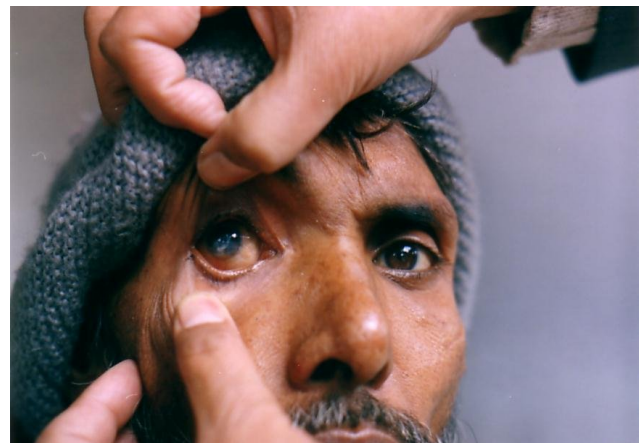

Fig 7. A case of corneal ulcer with all the features of dry conjunctiva. (photographed after permission from the patient, by Dr. Monish Gopal)

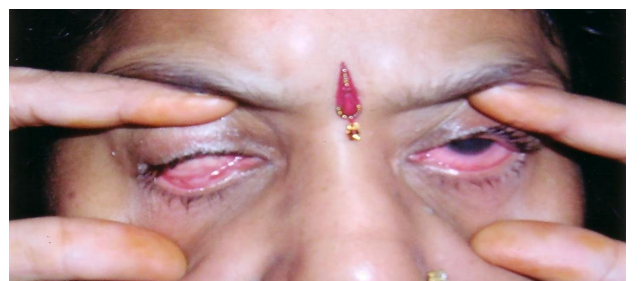

Fig 8. This patient had very severe dry eye following a prolonged course of t/t for suspected Toxoplasmosis with high doses of Sulphonamide & Deraprim . She had keratinisation of bulbar as well as palpebral conjunctiva with mucoid discharge , dense

corneal opacities and fine hair in the openings of meibomian glands that have to be epilated frequently to relieve symptoms. (photo graphed after permission from the patient, by Dr. Monish Gopal)

Dry eye may also be associated with laser in situ keratomileusis (LASIK). Typically, the dry eye that is associated with LASIK is transient and most severe in the first six post-operative months. There are three theories that exist to describe the mechanism. The first and most popular theory is that decreased tear fluid production is caused by the severing of the corneal nerves. This results in a decrease in the neural sensory feedback to the main and accessory lacrimal glands. The second theory is that the suction ring used during LASIK causes disruption of the limbal goblet cells, leading to decreased mucin production. The third theory is that alteration of the corneal surface and curvature alters tear flow. All patients who have had LASIK performed should be monitored closely for signs and symptoms of dry eye [5].

Lacrimal gland tear production can be determined clinically by means of a Schirmer test without anaesthesia (Schirmer 1), or by other more sophisticated tests for the evaluation of aqueous tear production and turnover.

Additional tests to determine whether the aqueous tear deficiency is associated with systemic immune dysfunction (SS) or is related to other causes of lacrimal gland dysfunction should be performed in patients with aqueous tear-deficient dry eye [8]. Lacrimal gland secretory dysfunction, ocular surface disease (termed keratoconjunctivitis sicca or KCS), and corneal complications, such as filamentary keratitis and ulceration, occur in a greater percentage in patients with SS than in those with non-SS tear fluid deficiency [9]. SS patients also have greater ocular surface epithelial pathology than patients with non-SS tear fluid deficiency. [9]SS patients show significantly greater corneal fluorescein staining and exposure zone rose-bengal staining than patients with non-SS tear fluid deficiency. In contrast to traditional reports that rose-bengal stains either dead or devitalized epithelial cells on the ocular surface, it is now known that rose-bengal can stain living cells devoid of tear components and mucins in particular [10]. Tear fluid deficiency associated with SS can be distinguished from non-SS causes by evaluating patients for serologic markers of immune dysfunction in addition to differences in ocular

diagnostic tests. SS patients have significant elevations of serum antibodies including antinuclear antibodies (ANAs), rheumatoid factors (RFs), and Sjogren's syndrome antibodies A and B (SS-A, SS-B) [11]. Diagnosis for patients with moderate to severe aqueous tear deficiency can be made by using one or more of the following tests: tear break-up time test, ocular surface dye staining pattern (rose bengal, fluorescein, or lissamine green), and the Schirmer test. The Schirmer test can disrupt tear film stability and cause false-positive ocular surface dye staining. Therefore, these tests should be performed in this sequence. Corneal sensation should be assessed when trigeminal nerve dysfunction is suspected [12]. Patients with significant dry eyes, other signs and symptoms of an autoimmune disorder, such as dry mouth, or a family history of an autoimmune disorder should undergo laboratory and clinical evaluation for autoimmune disorders.

Treatment

Avoiding potentially exacerbating exogenous factors, such as use of antihistamines and diuretics, environmental factors such as air drafts and low-humidity environments and exacerbating medications can help patients with a clinical diagnosis of mild dry eye. Measures such as humidifying ambient air and avoiding air drafts by using shields and by changing the characteristics of airflow at work, at home, and in the car may help. Lowering the computer screen to below eye level to decrease lid aperture and taking regular breaks and blinking frequently during long sessions in front of the computer may decrease the discomfort associated with computer and reading activities. Ocular factors, such as blepharitis, which contribute to dry eye, should also be treated. Tear substitutes should be used [13].

As the severity of the dry eye increases, aqueous enhancement of the eye using either topical agents or external means is appropriate. Artificial tears should be used frequently [14], but its practicality may depend on the life-style or manual dexterity of the patient. Emulsions, gels, and ointments can be used. Non-preserved tear substitutes are preferable if the patient uses them more than four to six times a day. Patients who demonstrate persistent symptoms or significant surface drying are noted despite the above measures. Those who are unable to instill tears frequently should be considered for punctal occlusion. Plugs made of silicone or thermal labile polymer can be surgically lodged at

the punctal orifice to accomplish punctal occlusion [15-21]. Semi-permanent plugs have the advantage of being reversible if the patient develops symptoms of epiphora and may be retained for many years without complications. They are typically dislodged and lost or displaced into the lacrimal drainage system. Displacement into the lacrimal system may result in passage through the system, continued residence with partial blockage of tear flow, or rarely, blockage with secondary infection. Surgical removal is rarely necessary. Punctal occlusion can also be accomplished permanently by means of thermal or laser cautery although the procedure has its own disadvantages. Non-invasive therapies, such as spectacle side shields, moisture inserts, and moisture, can be used, but they may be poorly tolerated because of the negative cosmetic effect. In patients with combined dry eye and dry mouth (Sjögren's syndrome), oral medications are also available to treat severe dry eyes [22-24].

Cholinergic agonists, pilocarpine, and cevimeline have been approved by the Food and Drug Administration to treat the symptoms of dry mouth in patients with Sjögren's syndrome. These medications bind to muscarinic receptors that stimulate the secretion of the salivary and sweat glands and appear to improve tear production. A fungal-derived peptide named Cyclosporine prevents activation and nuclear translocation of cytoplasmic transcription factors that are required for T-cell activation and inflammatory cytokine production. It also inhibits mitochondrial pathways of apoptosis. Topical cyclosporine has been reported to increase aqueous tear production and decrease ocular irritation symptoms in clinical trials for the treatment of KCS [25,26]. Restasis™ (.05% cyclosporine ophthalmic emulsion) can be effective in treating dry eye that has an underlying inflammatory component. Studies have shown that inflammation and infiltration of the lacrimal gland is significantly reduced when this medication is used topically BID. Past clinical trials have indicated that **Restasis™** increased tear production (measured by Schirmers) in patients with severe dry eye. It is important to realize that due to the life span of the typical T cell, it may take 3 to 6 months to note the effect of topical cyclosporine.

Corticosteroids have been reported to decrease ocular irritation symptoms and corneal fluorescein staining and to improve filamentary keratitis [27],[28]. The use of low-dose corticosteroid therapy at infrequent intervals for a short term (two

weeks) is effective for the suppression of irritation secondary to inflammation. Unfortunately, topical steroids are only beneficial for short time use due to potential risks, such as cataract formation, IOP elevation, and secondary infection [5].

In patients with Sjögren's syndrome, autologous serum drops have been reported to improve ocular irritation symptoms and conjunctival and corneal dye staining [29]. The tears contain growth factors including epidermal growth factor (EGF) and transforming growth factor β (TGF- β). While EGF accelerates corneal epithelial proliferation, (TGF- β) is expected to control epithelial proliferation and maintain cells in an undifferentiated state. Autologous human serum can be used on the eyes because it contains the same growth factors that are present in the tears. As a consequence, it is now possible to create eye drops from blood samples collected from individuals with dry eye. Also, components such as IgG, lysozyme, and complement, all of which are present in serum, may serve to provide additional anti-infective properties to an otherwise compromised surface. In a recent study comparing topical autologous serum agents with conventional lubricants, an improvement was observed, both in impression cytology score and in subjective comfort. At present, the minimal concentration of serum required to yield the most optimum result is yet to be elucidated. This would have implications both on the number of blood donations required each year and on the long-term effects on the ocular surface. Future investigations are thus required to address these issues [30].

Omega 3 fatty acid supplementation is also currently being utilized as an adjunct treatment for the dry eye disease. The Women's Health Study presented data collected from over 32,000 women regarding the relationship between dietary habits and dry eye. The study demonstrated that women who ingested maximum omega 3 fatty acids were the least likely to suffer from dry eye. Although the exact mechanism is unknown, Omega 3 supplementation seems to aid in the treatment of dry eye by decreasing glandular inflammation and by restoring meiboman gland function [5]. Evaporative dry eye is caused by meibomian gland dysfunction, a condition that is often associated with blepharitis and/or certain forms of skin disease, such as acne rosacea. The goal of treatment in these patients is to restore the meibomian gland function and this can be achieved by observing lid hygiene.

In cases where meibomian gland dysfunction is associated with skin disease, oral tetracycline and its derivative (doxycycline) are the treatments of choice [5]. Current research is examining the use of androgens in the treatment of dry eye. As stated earlier, androgens seem to play an important role in modulating meibomian and lacrimal gland function. Inflammation in the lacrimal gland and ocular surface has also been shown to be suppressed by systemic androgens. The future of the use of androgens in the treatment of dry eye appears promising. Proper management of the dry eye patient can be achieved by a thorough understanding of anatomy, physiology, evaluation, and treatment. Recent studies have strengthened the understanding of this complicated disease and opened the door to new treatment options. Optometrists can play a pivotal role in identifying and helping patients of dry eye [5].

Conclusion

Until recently, dry eye was considered to be a difficult to treat and time-consuming clinical condition. This led many patients to live with the condition, and many ophthalmologists to shy away from actively seeking out and treating them. The emergence of several new-generation artificial tears and wetting agents, which can be used as a prescription for dry eye medication, and new dietary supplements have made the ailment much more manageable. According to ophthalmologists, patients can be treated effectively and efficiently now. Also, a general awareness of dry eye has arisen. Pharmaceutical companies, media-marketing campaigns, and medical information on the internet have publicized the condition and have informed people regarding potential treatments. These factors have made it easy for physicians to actively seek out and treat dry eye patients. Effective diagnosis is the key for the classification and treatment of dry eye [31]. The most important aspects of caring for patients with dry eye are to educate them about the chronic nature of the disease process and to provide specific instructions for therapeutic regimen. The frequency and extent of the follow-up evaluation will depend on the severity of disease, the therapeutic approach, and the response to the therapy.

References

1. Brewitt H, Sistani F. Dry eye disease: the scale of the problem. *Surv Ophthalmol* 2001;45(Supp 2):S199-202.
2. Schein OD, Munoz B, Tielsch JM, et al. Prevalence of dry eye among the elderly. *Am J Ophthalmol* 1997;124:723-8.
3. Lemp MA. Report of the National Eye Institute/Industry workshop on Clinical Trials in Dry Eyes. *Clao J* 1995;21:221-32.
4. Pflugfelder SC. Differential diagnosis of dry eye conditions. *Adv Dent Res* April 1996;W(1):9-12.
5. Current and future issues in the management of dry eye. James E. Slottlemyer
6. Mathers WD, Shields WJ, Sachdev MS. Meibomian gland dysfunction in chronic blepharitis. *Cornea*: (1991a):10:277-285.
7. Mathers WD, Shields WJ, Sachdev MS, Petroll WM, Jester JV. Meibomian gland morphology and tear osmolarity: changes with accutane therapy. *Cornea*: (1991b):10:286-290.
8. Fox RI. Systemic diseases associated with dry eye. *Int Ophthalmol Clin*. 1994;34: 71-88.
9. Pflugfelder SC, Tseng SCG, Sanabria O, Kell H, Garcia CG, Felix C, et al. Diagnostic classification of conditions causing ocular irritation (abstract). *Invest Ophthalmol Vis Sci* 1994; 35 (Suppl) : 1692.
10. Feenstra RPG, Tseng SCG. What is actually stained by Rose-bengal ? *Arch Ophthalmol* 1992; 10: 984-993.
11. Pflugfelder SC, Tseng SCG, Pepose JS, Fletcher MA, Klimas NG, Feuer W. Chronic Epstein-Barr viral infection and immunologic dysfunction in patients with aqueous tear deficiency. *Ophthalmology* 1990; 97: 313-323.
12. Heigle TJ, Pflugfelder SC. Aqueous tear production in patients with neurotrophic keratitis. *Cornea* 1996;15:135-8.
13. Lemp MA. Artificial tear solutions. *Int Ophthalmol Clin* 1973;13:221-9.
14. DeLuise VP, Peterson WS. The use of topical Healon tears in the management of refractory dry-eye syndrome. *Ann Ophthalmol* 1984;16:823-4.
15. Blepharitis, Preferred Practice Pattern. San Francisco: American Academy of Ophthalmology, 1998.
16. Punctal occlusion for the dry eye. Three-year revision. American Academy of Ophthalmology. *Ophthalmology* 1997;104:1521-4.
17. Awan KJ. Laser punctoplasty for the treatment of punctal stenosis. *Am J Ophthalmol* 1985;100:341-2.
18. Dohlman CH. Punctal occlusion in keratoconjunctivitis sicca. *Ophthalmology* 1978;85:1277-81.
19. Willis RM, Folberg R, Krachmer JH, Holland EJ. The treatment of aqueous-deficient dry eye

- with removable punctal plugs. A clinical and impression-cytologic study. *Ophthalmology* 1987;94:514-8.
20. Tuberville AW, Frederick WR, Wood TO. Punctal occlusion in tear deficiency syndromes. *Ophthalmology* 1982;89:1170-2.
 21. Lamberts DW. Punctal occlusion. *Int Ophthalmol Clin* 1994;34:145-50.
 22. Vivino FB, Al-Hashimi I, Khan Z, et al. Pilocarpine tablets for the treatment of dry mouth and dry eye symptoms in patients with Sjogren syndrome: a randomized, placebo-controlled, fixed-dose, multicenter trial. P92-01 Study Group. *Arch Intern Med* 1999;159:174-81.
 23. Fox RI, Konttinen Y, Fisher A. Use of muscarinic agonists in the treatment of Sjogren's syndrome. *Clin Immunol* 2001;101:249-63.
 24. Petrone D, Condemi JJ, Fife R, et al. A double-blind, randomized, placebo-controlled study of cevimeline in Sjogren's syndrome patients with xerostomia and keratoconjunctivitis sicca. *Arthritis Rheum* 2002;46:748-54.
 25. Gunduz K, Ozdemir O. Topical cyclosporin treatment of keratoconjunctivitis sicca in secondary Sjogren's syndrome. *Acta Ophthalmol (Copenh)* 1994;72:438-42.
 26. Sall K, Stevenson OD, Mundorf TK, Reis BL. Two multicenter, randomized studies of the efficacy and safety of cyclosporine ophthalmic emulsion in moderate to severe dry eye disease. CsA Phase 3 Study Group. *Ophthalmology* 2000;107:631-9.
 27. Marsh P, Pflugfelder SC. Topical nonpreserved methylprednisolone therapy for keratoconjunctivitis sicca in Sjogren syndrome. *Ophthalmology* 1999;106:811-6.
 28. Prabhasawat P, Tseng SC. Frequent association of delayed tear clearance in ocular irritation. *Br J Ophthalmol* 1998;82:666-75.
 29. Tsubota K, Goto E, Fujita H, et al. Treatment of dry eye by autologous serum application in Sjogren's syndrome. *Br J Ophthalmol* 1999;83:390-5.
 30. Therapeutic management of dry eye, Greg Heath Dec 3, 2004
 31. *Ophthalmology Management* John Parkinson, Feb 2005